



## PATIENT

Rosie Schering

## SPECIES

Canine

## BREED

Plott Hound

## SEX

FS

## AGE

3yr

## WEIGHT

32kg

## INTERPRETED BY

R. McKenzie Daniel,  
DVM, DABVP  
(Canine and Feline)

## IMAGING PERFORMED BY

Seyler

## HOSPITAL NAME

Wilvet South

## REFERRING VET

Seyler

## INVOICE 24102

## DATE

03/04/2026

## PRESENTING CLINICAL SIGNS

Patient presented with a history of recent seizures and is on phenobarbital for seizure control. First seizure December, 2025, started phenobarbital after second seizure in Jan 2026. Seen 3/3 at RDVM for drooling and lethargy. Patient was found to have a fever and severely low neutrophils and platelets. SQF, Cerenia and Rx for metronidazole given. Patient presents here at ER for continued lethargy and fever.

Abnormal PE/Chem/CBC/UA Results: EPOC: HCT 45, BEb -6.2, BEecf -8, mTCO2 16, all other wnl CBC: HCT 44.4, WBC 1.22, Neut 0.10, lymphocytes 0.1, platelets 17, all other wnl Chem 10: ALP 405, all other wnl Blood smear w/ add on review- pending. AUS - to be performed soon. Inn aspirates at same time as AUS

## ULTRASONOGRAPHIC EXAMINATION OF THE ABDOMEN

### Urinary System

The urinary bladder, trigone, cystourethral junction, and visible pelvic urethra to a depth of 3 cm exhibited normal thickness and tone. Anechoic urine was present in the lumen with no evidence of urine/lumen sediment, mineral, or calculi. The ureteral papillae were normal. The ureters were not visible which is normal. No evidence of inflammatory or neoplastic changes was noted.

Normal size and margination were present in the kidneys. A normal 1:3 cortex / medulla ratio and normal corticomedullary definition were maintained. The echogenicity of the cortex was similar to or slightly less than normal liver parenchyma while the medulla echogenicity was hypoechoic to the cortex with no evidence of pelvic dilation. The left kidney measured 6.8 cm in length. The right kidney measured 6.8 cm in length.

The area of the aortic trifurcation was free of pathology.

### Adrenal Glands

The left adrenal gland was uniform in size and contour with a uniformly hypoechoic parenchyma. The left adrenal gland measured 0.75 cm width at the caudal pole. The right adrenal gland was not definitively visualized, no overt pathology in the area of the right adrenal gland.

### Spleen

The spleen exhibited subjective borderline to mild enlargement with a finely textured and homogenous parenchyma which was hyperechoic to the liver and renal cortical parenchyma. The capsule was smooth and regular without apparent expansion. The splenic vasculature at the hilus was normal in volume with no evidence of congestion or thrombosis. Acute to chronic inflammatory, neoplastic, or benign parenchyma changes were not noted.

### Liver/Gallbladder

The liver presented subjective mildly enlarged in size. The parenchyma of the liver was subjectively normal in echogenicity compared to the spleen and renal cortices. The liver parenchyma was uniform with a mildly coarse echotexture. Normal vascular volume. The capsule of the liver was symmetrically rounded to mildly swollen in margination. The hepatic and portal vasculature were normal in



## PATIENT

Rosie Schering

## SPECIES

Canine

## BREED

Plott Hound

## SEX

FS

## AGE

3yr

## WEIGHT

32kg

## INTERPRETED BY

R. McKenzie Daniel,  
DVM, DABVP  
(Canine and Feline)

## IMAGING PERFORMED BY

Seyler

## HOSPITAL NAME

Wilvet South

## REFERRING VET

Seyler

## INVOICE

24102

## DATE

03/04/2026

appearance without signs of congestion. The gallbladder was non-distended in size with mild nonorganized debris. The cystic and common bile ducts were normal.

### **Gastrointestinal**

The stomach was indistinctly visualized with no evidence of gastric distension with retained ingesta or fluid.

The small intestine presented intact wall layering with 1:3 muscularis/mucosa ratio. Mild segmental duodenojejunal ileus not consistent with obstructive pattern and segmental gas present to the level of the colon.

Normal visible colon wall layers were present with apparent formed feces in lumen.

### **Pancreas**

The area of the pancreas was sonographically normal.

### **Free Abdomen**

No omental masses, overt lymphadenopathy or peritoneal effusion was present.

## **ULTRASONOGRAPHIC FINDINGS**

### **Primary**

- Hepatomegaly with borderline to mild concurrent splenomegaly
- Non-distended stomach with mild non-obstructive intestinal ileus
- Normal area of pancreas
- Mild gallbladder debris

## **INTERPRETATION OF THE FINDINGS & FURTHER RECOMMENDATIONS**

The hepatomegaly and borderline to mild splenomegaly are non-specific yet suggestive of benign criteria with considerations including vacuolar, reactive or metabolic hepatopathy, medication associated hepatopathy, i.e. phenobarbital, non-obstructive cholestasis, hyperplasia, hematopoiesis, possible incidental splenitis with occult hepatosplenic neoplasia thought less likely. If normal clotting status and using 25ga needle, a screening hepatosplenic FNA cytology could be considered for further assessment.

No evidence of gastrointestinal mechanical obstruction with potential nonspecific gastroenteritis. Hepatogastrointestinal support is recommended. A spec CPL or GI panel to include PLT/TLI/cobalamin and folate in conjunction with pending blood smear to assess for additional occult disease could be considered.

Empirical coverage for potential sepsis given severe neutropenia is recommended.



**PATIENT**

Rosie Schering

**SPECIES**

Canine

**BREED**

Plott Hound

**SEX**

FS

**AGE**

3yr

**WEIGHT**

32kg

**INTERPRETED BY**

R. McKenzie Daniel,  
DVM, DABVP  
(Canine and Feline)

**IMAGING PERFORMED BY**

Seyler

**HOSPITAL NAME**

Wilvet South

**REFERRING VET**

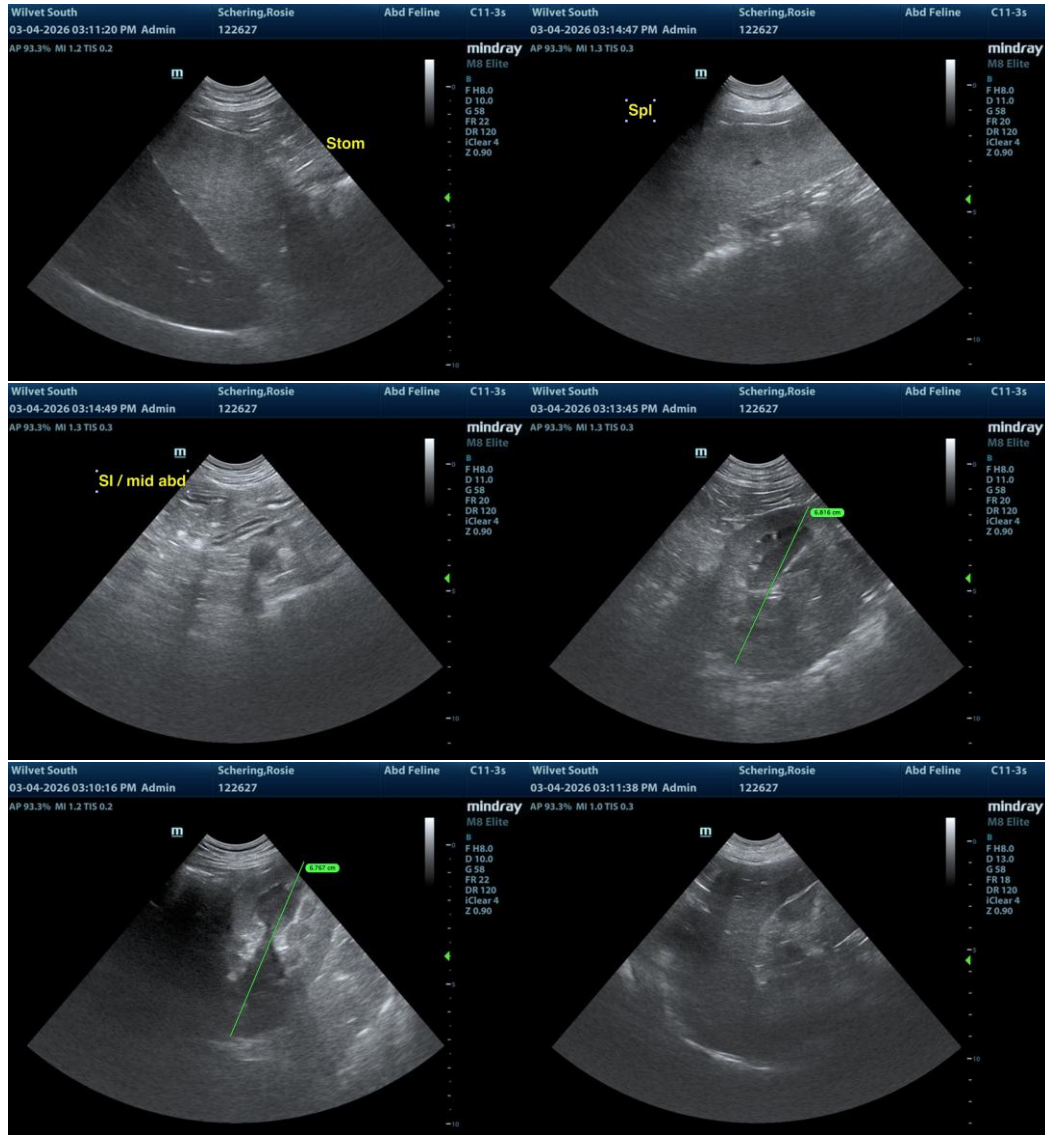
Seyler

**INVOICE**

24102

**DATE**

03/04/2026





**PATIENT**

Rosie Schering

**SPECIES**

Canine

**BREED**

Plott Hound

**SEX**

FS

**AGE**

3yr

**WEIGHT**

32kg

**INTERPRETED BY**

R. McKenzie Daniel,  
DVM, DABVP  
(Canine and Feline)

**IMAGING PERFORMED BY**

Seyler

**HOSPITAL NAME**

Wilvet South

**REFERRING VET**

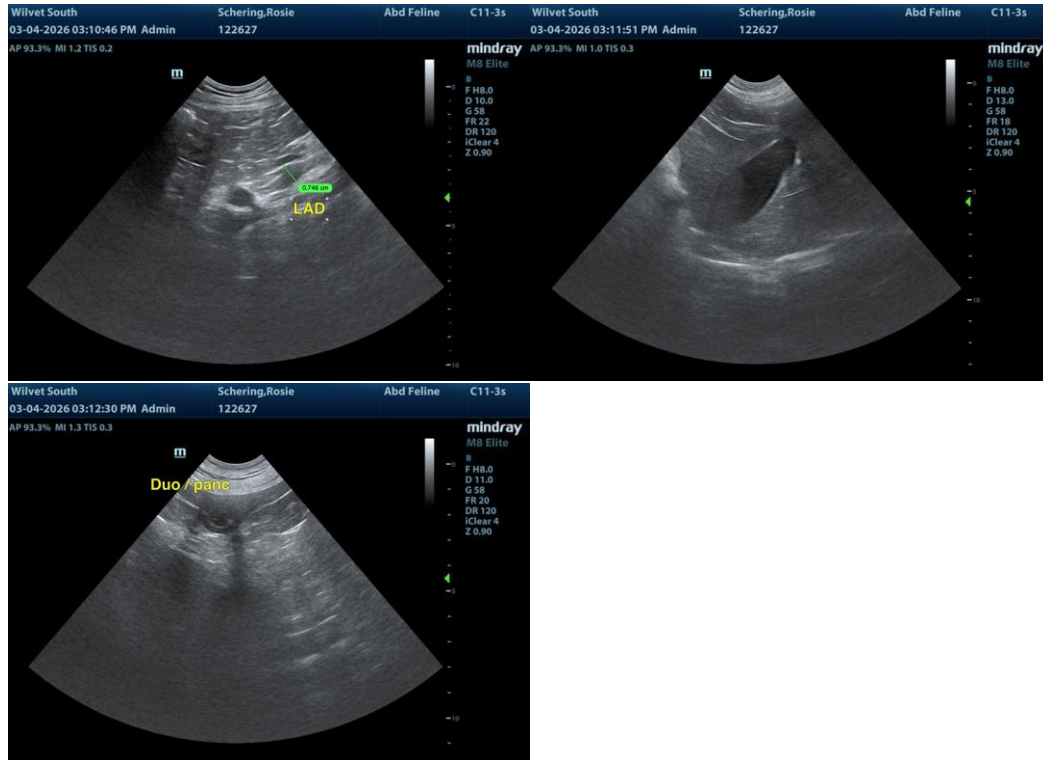
Seyler

**INVOICE**

24102

**DATE**

03/04/2026



The information and recommendations provided are based on the images presented by the referring veterinarian/sonographer. No evaluation can be communicated regarding pathology that was not visible in the image/video clips provided.

Thank you for this referral. If the clinical or image interpretation does not parallel your findings or if I can be of any further assistance, please contact me.

R. McKenzie Daniel, DVM, DABVP (Canine/Feline Practice)  
[info@sonopath.com](mailto:info@sonopath.com)